

## Ileal Atresia Mimicking Hirschsprung Disease on Contrast Study: A Case Report and Diagnostic Re-evaluation

Anisa Ika Pratiwi<sup>1\*</sup>, Ibnu Sina Ibrohim<sup>2</sup>

<sup>1</sup>Department of Surgery, Faculty of Medicine, Universitas Sebelas Maret/Dr. Moewardi Regional General Hospital, Surakarta, Indonesia

<sup>2</sup>Department of Pediatric Surgery, Faculty of Medicine, Universitas Sebelas Maret/Dr. Moewardi Regional General Hospital, Surakarta, Indonesia

### ARTICLE INFO

#### Keywords:

Congenital  
Diagnostic pitfall  
Hirschsprung disease  
Ileal Atresia  
Neonate

#### \*Corresponding author:

Anisa Ika Pratiwi

#### E-mail address:

[anisaiikapratiwi13@gmail.com](mailto:anisaiikapratiwi13@gmail.com)

All authors have reviewed and approved the final version of the manuscript.

<https://doi.org/10.37275/oaijmr.v5i5.770>

### ABSTRACT

The differentiation between congenital causes of neonatal bowel obstruction, such as ileal atresia and Hirschsprung disease, is paramount for appropriate surgical planning. While clinically similar, their radiological findings can overlap, creating significant diagnostic challenges. Ileal atresia is a congenital anomaly characterized by the incomplete development of the ileum, resulting in intestinal obstruction. The aim of this study is to highlight the limitations of contrast studies in neonatal bowel obstruction and to reinforce the principle that in the face of discordant clinical and radiological evidence. We present the case of a full-term female neonate, born at 39 weeks of gestation, who developed symptoms of green vomiting and delayed bowel movements on her second day of life. An initial colon in loop contrast study at eight days of age was suggestive of short-segment Hirschsprung disease, showing a narrowed rectal lumen and a transition zone in the rectosigmoid region. However, due to persistent signs of distal bowel obstruction, surgical exploration was performed on the ninth day of life. Intraoperatively, the diagnosis was revised to Type 3A ileal atresia located 20 cm from the ileocecal junction, with significant adhesions. The management involved adhesiolysis, resection of the atretic ileal segment, and a primary ileo-ascending anastomosis. The postoperative course was complicated by hypovolemic shock and suspected sepsis neonatorum, which were managed successfully with intensive care support, including intravenous antibiotics and parenteral nutrition. The patient showed significant improvement by the fifth postoperative day and was discharged with normal gastrointestinal function. In conclusion, this case underscores a critical diagnostic pitfall where the 'microcolon of disuse' in distal ileal atresia radiologically mimicked the transition zone of Hirschsprung disease. It highlights that while contrast studies are invaluable, a high index of clinical suspicion and readiness for surgical exploration are essential for accurate diagnosis and timely intervention in complex cases of neonatal bowel obstruction.

### 1. Introduction

Neonatal intestinal obstruction represents a significant and urgent challenge in pediatric surgery, encompassing a spectrum of congenital and acquired conditions that impede the normal passage of intestinal contents. These obstructions can occur at any point along the gastrointestinal tract, from the esophagus to the anus, and manifest within the first few hours to days of life. The classic clinical triad of

bilious vomiting, abdominal distension, and failure to pass meconium signals an obstruction distal to the ampulla of Vater and necessitates immediate investigation and management. The etiology of such obstructions is diverse, with congenital anomalies being the predominant cause. Among these, intestinal atresia and stenosis, malrotation with midgut volvulus, meconium ileus, and Hirschsprung disease are the most frequently encountered pathologies.<sup>1</sup>

Each of these conditions stems from distinct embryological failures and requires a specific therapeutic approach. Therefore, an accurate and prompt diagnosis is not merely academic but is crucial for guiding surgical strategy, preventing life-threatening complications like bowel perforation, sepsis, and short bowel syndrome, and ultimately determining the patient's survival and long-term quality of life.<sup>2</sup>

Ileal atresia, a primary focus of this report, is a congenital anomaly defined by the incomplete development and discontinuity of the ileal lumen.<sup>3</sup> It is one of the more common causes of neonatal intestinal obstruction, with an estimated incidence of approximately 1 in 5,000 to 1 in 10,000 live births. The condition is widely believed to result from an ischemic event or vascular accident during fetal life, such as thrombosis, embolism, or volvulus involving the mesenteric vessels supplying a segment of the fetal intestine. This vascular disruption leads to necrosis and subsequent resorption of the affected bowel segment, creating a gap or a membranous blockage. Ileal atresia is classified into distinct types based on its anatomical configuration.<sup>4</sup> Type 1 involves an intact bowel wall with an internal membranous web causing the obstruction. Type 2 is characterized by two blind-ending bowel loops connected by a fibrous cord. Type 3A involves a complete separation of the two bowel ends with an associated V-shaped mesenteric defect, as was observed in the present case. Type 3B, where there is a complete separation of the ileum with no connection between the proximal and distal ends, is a more severe form with extensive mesenteric defects. Type 4 consists of multiple atresias along the length of the bowel. The clinical presentation is typically marked by symptoms of distal obstruction within the first 24-48 hours of life. Treatment is exclusively surgical, involving resection of the atretic segment and the dilated, dysfunctional proximal bowel, followed by a primary anastomosis to restore intestinal continuity. The prognosis is generally favorable for isolated atresia, particularly when diagnosed and treated promptly.<sup>5</sup>

In the differential diagnosis of distal neonatal obstruction, Hirschsprung disease (congenital aganglionic megacolon) presents a significant challenge due to its overlapping clinical signs. Hirschsprung disease is a developmental disorder characterized by the absence of ganglion cells (Meissner's and Auerbach's plexuses) in the submucosal and myenteric layers of the distal intestine. This failure results from an arrest in the craniocaudal migration of neural crest cells during embryogenesis, typically between the 5th and 12th weeks of gestation. The aganglionic segment remains in a state of tonic contraction, causing a functional obstruction with massive dilation of the proximal, normally innervated bowel. Its incidence is approximately 1 in 5,000 live births. While most cases involve the rectosigmoid region (short-segment disease), the aganglionosis can extend to involve the entire colon (long-segment disease) or even the small intestine (total intestinal aganglionosis).<sup>6</sup> The clinical hallmarks—delayed meconium passage, abdominal distension, and bilious emesis—are often indistinguishable from those of ileal atresia.

The diagnostic workup for these conditions relies heavily on radiological imaging. Plain abdominal radiography is the initial step, often revealing dilated loops of bowel with air-fluid levels, suggestive of obstruction. A contrast enema (or colon in loop study) is then typically performed to differentiate between these pathologies.<sup>7</sup> In Hirschsprung disease, the contrast study classically demonstrates a narrow distal aganglionic segment with a funnel-shaped transition zone to a dilated proximal colon. In distal ileal atresia, the enema is expected to show a "microcolon" or an unused, small-caliber colon, as it has not received fetal intestinal contents (meconium) during gestation.<sup>8</sup> However, this distinction is not always clear-cut. The unused colon in distal atresia can sometimes be misinterpreted. The junction between the unused microcolon and the more proximal colon, which may have received some succus entericus, can occasionally simulate a transition zone. Conversely, a neonate with total colonic aganglionosis

might also present with a diffuse microcolon, further confounding the radiological picture. This potential for misinterpretation represents a significant clinical pitfall, as the surgical management for the two conditions is fundamentally different. Ileal atresia requires a laparotomy with resection and anastomosis, while Hirschsprung disease requires a pull-through procedure, often preceded by a diverting stoma and confirmed with a rectal biopsy.<sup>9</sup>

The novelty of this case report lies in its detailed illustration of this specific diagnostic dilemma, where radiological findings from a contrast enema strongly suggested Hirschsprung disease, leading to a potential misdirection of the surgical plan. This report meticulously documents the clinical reasoning, the misleading radiological evidence, the eventual intraoperative revision of the diagnosis, and the successful management of a complex case of Type 3A ileal atresia.<sup>10</sup> This study aimed to highlight the limitations of contrast studies in certain contexts of neonatal bowel obstruction and to reinforce the principle that, in the face of discordant clinical and radiological evidence, a high index of suspicion and timely surgical exploration remain the cornerstones of effective management.

## **2. Case Presentation**

This report details the case of a female neonate who was born to a 28-year-old G2P1 mother at 39 weeks of gestation via spontaneous vaginal delivery. The pregnancy was monitored with routine antenatal care, and prenatal ultrasounds were reported as normal, with no evidence of polyhydramnios or dilated bowel loops. The infant's birth weight was 3013 grams and her length was 50 cm. Apgar scores were 8 and 9 at one and five minutes, respectively. The immediate postnatal period was reported as uneventful. The neonate was put to the breast within the first hour of life and initially fed well. She passed meconium within the first 12 hours, which was noted to be of a watery consistency, a subtle but significant deviation from the typical thick, tenacious character of normal meconium.

On the second day of life, the neonate's clinical condition began to deteriorate. She developed recurrent episodes of non-projectile, green-colored (bilious) vomiting after every feed. Concurrently, her abdomen became progressively distended, and she had no further bowel movements. Due to these concerning signs of gastrointestinal obstruction, she was transferred to the Neonatal Intensive Care Unit (NICU) at our tertiary care facility for further evaluation and management.

Upon admission to the NICU, the infant appeared lethargic and in moderate distress. Her vital signs were as follows: heart rate of 165 beats per minute, respiratory rate of 70 breaths per minute with mild subcostal retractions, temperature of 37.1°C, and oxygen saturation of 94% on room air. Physical examination revealed a significantly distended, tense, and diffusely tender abdomen. The abdominal girth was measured at 38 cm. Bowel sounds were minimal on auscultation. Insertion of an orogastric tube yielded 25 mL of green-colored gastric residue, confirming the presence of bilious fluid. The remainder of the systemic examination was unremarkable. A comprehensive summary of the patient's initial clinical and diagnostic findings is presented in Table 1. This table encapsulates the key data points from the patient's history, physical examination, and initial laboratory and radiological investigations that collectively built the picture of a significant neonatal intestinal obstruction and guided the initial, albeit misleading, diagnostic pathway.

An initial plain abdominal X-ray (babygram) in supine and left lateral decubitus positions was performed on the third day of life. The radiographs demonstrated multiple, significantly dilated loops of small bowel, with several air-fluid levels visible on the decubitus view (Figure 1 A-D). There was a notable paucity of gas in the distal abdomen and pelvic region, a pattern highly suggestive of a distal small bowel obstruction. To further delineate the anatomy of the distal bowel and to differentiate between potential causes, a water-soluble contrast enema was performed on the eighth day of life. The study revealed

that the contrast material filled the rectum, sigmoid colon, descending colon, splenic flexure, and a portion of the transverse colon. Critically, the examination demonstrated a narrowed lumen in the rectal and rectosigmoid segment, with a subsequent, more dilated sigmoid colon, leading to a provisional diagnosis of congenital megacolon of the short-segment type (Hirschsprung disease).

Despite this radiological diagnosis, the surgical team remained cautious. The degree of proximal small bowel dilation on the initial X-rays seemed more pronounced than typically seen with short-segment Hirschsprung's, and the clinical picture of a complete, early-onset obstruction was compelling for a mechanical atresia. Given the persistent vomiting, increasing abdominal distension, and the overall clinical picture of a complete distal obstruction, the decision was made to proceed with surgical exploration on the ninth day of life. The comprehensive treatment pathway, from the definitive surgical intervention to the details of the intensive postoperative care and subsequent follow-up, is outlined in Table 2. This table provides a chronological summary of the management strategy that was crucial in navigating the patient's complex course and ensuring a successful recovery.

The infant underwent an exploratory laparotomy through a transverse supraumbilical incision. The operative findings immediately clarified the diagnosis. There was a significant, dense adhesion involving the distal ileum. Following careful adhesiolysis, a Type 3A ileal atresia was identified. The atresia was located approximately 20 cm proximal to the ileocecal junction and consisted of a blind-ending, bulbous proximal ileal segment and a disconnected, collapsed, micro-caliber distal ileal segment, with a clear V-shaped defect in the associated mesentery. The entire colon was of a narrow caliber, consistent with a 'microcolon of disuse'. The surgical procedure involved the resection of the atretic distal ileum and approximately 10 cm of the dilated, dysfunctional proximal ileal segment. A primary end-to-back ileo-ascending anastomosis was meticulously performed. The immediate postoperative period was challenging, marked by hypovolemic shock and confirmed *Escherichia coli* sepsis, which were successfully managed in the NICU with intensive support. The patient's condition stabilized, allowing for the gradual introduction of enteral feeding and eventual discharge on the fifth postoperative day, with a favorable outcome noted at the follow-up visit on the 11th day post-operation.

Table 1. Summary of clinical and diagnostic findings.

Parameter	Finding
<b>Demographics</b>	
Age at presentation	2 days of life
Gender	Female
Gestational age	39 weeks
Birth weight	3013 grams
<b>Presenting symptoms</b>	
Onset of symptoms	Day 2 of life
Vomiting	Recurrent, bilious (green-colored)
Meconium passage	Passed watery meconium initially, then no further stool
<b>Physical examination</b>	
General	Lethargic, in moderate distress
Abdomen	Significantly distended, tense, diffusely tender
Bowel sounds	Minimal
Gastric residue	25 mL, bilious
<b>Laboratory findings</b>	
White blood cell count	18,500/mm <sup>3</sup> (with left shift)
C-reactive protein (CRP)	15 mg/L
Serum sodium	130 mmol/L
Serum chloride	92 mmol/L
<b>Radiological findings</b>	
Plain Abdominal X-ray	Multiple dilated small bowel loops, air-fluid levels, paucity of distal gas
Contrast enema	Narrowed rectum/rectosigmoid, dilated sigmoid; suggestive of a transition zone
<b>Preoperative diagnosis</b>	Suspected short-segment Hirschsprung disease

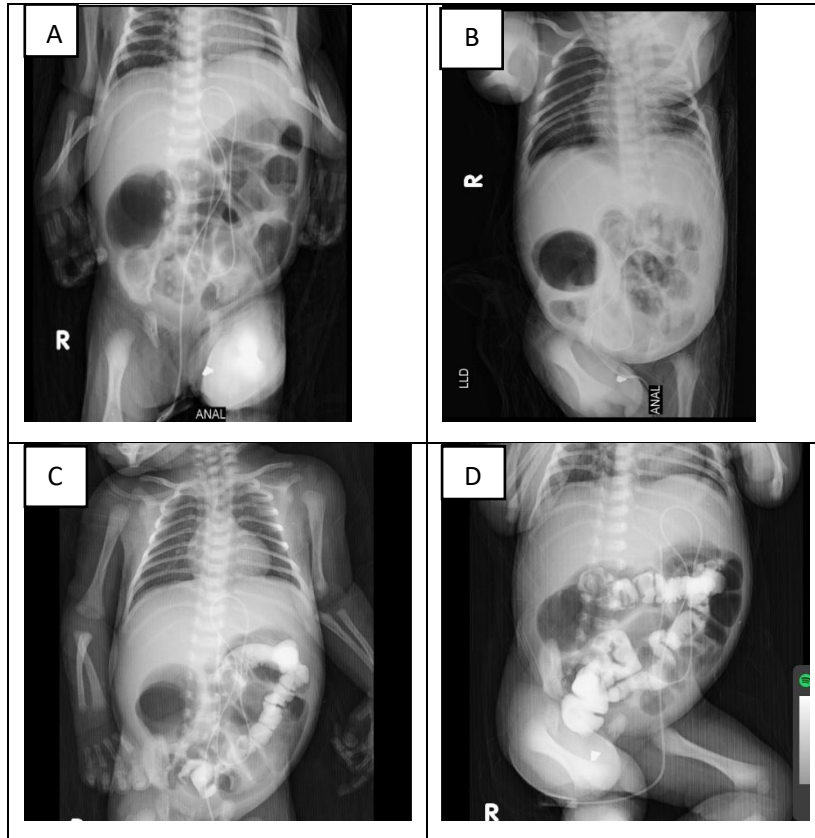


Figure 1. A. Plain supine position X-ray, B. Plain LLD position X-ray, C. Colon in loop, Contrast is seen filling the rectum, sigmoid colon, descending colon, splenic flexure, and part of the transverse colon. D. Colon in loop, Narrowing of the rectal lumen, and dilation of the sigmoid colon are observed.

Table 2. Summary of treatment and follow-up.

Parameter	Details
<b>Surgical procedure</b>	
Date of surgery	Day 9 of life
Procedure performed	Exploratory laparotomy, adhesiolysis, resection of ileal atresia, primary ileo-ascending anastomosis
Intraoperative findings	Type 3A ileal atresia 20 cm from ileocecal junction; massively dilated proximal ileum; distal microcolon
<b>Postoperative management</b>	
ICU admission	Yes, immediate postoperative
Respiratory support	Mechanical ventilation, extubated on Postoperative Day 3
Hemodynamic support	Fluid resuscitation, transient low-dose dopamine infusion for hypovolemic shock
Antibiotic therapy	Intravenous Ampicillin, Amikacin, Metronidazole for sepsis neonatorum ( <i>E. coli</i> )
Nutritional support	Total Parenteral Nutrition (TPN) initiated postoperatively; enteral feeding started on Postoperative Day 4
<b>Postoperative milestones</b>	
First passage of flatus	Postoperative Day 4
First passage of stool	Postoperative Day 5
Time to full enteral feeds	Postoperative Day 7
<b>Outcome</b>	
Length of hospital stay	7 days postoperatively (discharged on POD 5)
Follow-up	Day 11 post-operation: thriving, good clinical progress, no signs of obstruction

### 3. Discussion

The successful navigation of this complex case of neonatal intestinal obstruction offers a profound and multi-layered educational opportunity, touching upon the subtleties of clinical diagnosis, the fallibility of established imaging modalities, the fundamental distinctions in congenital pathophysiology, the intricacies of surgical decision-making, and the rigors of neonatal critical care.<sup>9</sup> This discussion aims to dissect these layers in extensive detail, moving beyond a simple recounting of events to explore the underlying scientific principles and clinical reasoning that defined this patient's journey. We will explore how a classic case of Type 3A ileal atresia presented under the convincing guise of Hirschsprung disease, creating a diagnostic conundrum that tested the core tenets of pediatric surgical practice.<sup>10</sup> By deconstructing this case, we can illuminate the critical thinking required to bridge the gap between initial presentation, misleading intermediate data, and definitive, life-saving intervention. The narrative of this neonate is not merely a report of a single event but a comprehensive illustration of the dynamic interplay between diagnostic acumen, surgical skill, and intensive care that forms the bedrock of modern neonatology and pediatric surgery. It is a story of recognizing the unexpected, questioning the apparent, and adhering to fundamental principles to steer a fragile life through a perilous storm towards a safe harbor.

At the very heart of this case lies the diagnostic conflict between the contrast enema findings and the overarching clinical picture—a conflict that represents one of the most classic and instructive pitfalls in neonatal surgery. The contrast study, a venerable tool in the diagnostic armamentarium, produced an image that was, by all conventional radiological criteria, highly suggestive of short-segment Hirschsprung disease.<sup>11</sup> It depicted what appeared to be a narrowed distal segment (the rectum and rectosigmoid colon) followed by a more capacious proximal segment (the sigmoid colon), creating a funnel-like appearance that radiologists are trained to identify as a transition zone.

This zone is pathognomonic for Hirschsprung disease, representing the anatomical point where the aganglionic, tonically constricted distal bowel meets the normally innervated, dilated proximal bowel.<sup>10</sup> The logic is sound, and in the majority of cases, this finding reliably leads to the correct diagnosis. However, in our patient, this radiological sign was a siren's call, luring the diagnostic process towards a completely erroneous conclusion. The intraoperative reality of a distal ileal atresia provided the definitive explanation: the entire colon was a 'microcolon of disuse'. The concept of the microcolon is central to understanding this diagnostic error. During fetal life, the intestine is not dormant; it is actively swallowing amniotic fluid, which mixes with sloughed intestinal cells, mucus, and bile to form meconium. This process distends the fetal bowel, particularly the colon, preparing it for its postnatal function. When a complete proximal obstruction like an ileal atresia exists, this flow of meconium is completely blocked. The colon, downstream from the obstruction, never receives this distending material. Consequently, it fails to develop its normal caliber and remains a thin, unused tube. When contrast material is introduced during an enema, it enters this uniformly narrow colon. The apparent "transition zone" was, in this case, a physiological artifact rather than an anatomical one. The rectum and distal sigmoid, being the most distal and muscular part of the colon, likely exhibited a greater degree of tonicity or resistance to the initial influx of contrast compared to the more proximal parts of the unused colon. This differential filling pressure and compliance created a gradient in caliber on the static images of the study, perfectly mimicking the morphology of a true aganglionic transition zone. This phenomenon is a stark reminder that radiological images are functional snapshots, not just anatomical maps, and their interpretation requires a deep understanding of the underlying physiology. The clinical context must always hold sway. The surgical team's decision to trust the clinical signs—the profound degree of small bowel dilation on plain films, which pointed to a more proximal and complete obstruction, and the sheer severity of the

early-onset symptoms—over the seemingly definitive contrast study was the pivotal moment of correct clinical judgment in this case.

To fully appreciate the diagnostic divergence, one must delve into the fundamentally different origins of ileal atresia and Hirschsprung disease. They are both congenital disorders leading to obstruction, but their embryological stories are written in entirely different languages—one of vascular catastrophe, the other of neural migration failure. Ileal atresia is widely accepted to be a consequence of a late-gestation intrauterine vascular accident. The developing fetal gut is suspended by the mesentery, a delicate fan-like structure containing its life-giving arteries and veins. This arrangement makes the bowel susceptible to twisting (volvulus), telescoping (intussusception), or becoming entrapped in a hernia.<sup>12</sup> Any such event can compromise the mesenteric blood supply to a segment of the intestine. This ischemia, if prolonged, leads to sterile necrosis. The body's natural response is to resorb the dead tissue, leaving behind a gap (as in Type 3A atresia), a fibrous cord (Type 2), or a thin membrane (Type 1). This entire process occurs in a bowel that has already formed its basic structure and, importantly, has already been populated by neural crest cells, meaning the bowel proximal and distal to the atresia is neurologically normal. This "vascular accident" theory is supported by several lines of evidence: the condition is almost never seen in stillborn fetuses aborted early in gestation, suggesting it is a late event; it can be experimentally reproduced in animal models by ligating mesenteric vessels; and it is often associated with other conditions that predispose to vascular compromise like malrotation and volvulus.

Hirschsprung disease, in stark contrast, is a neurocristopathy. Its story begins much earlier in fetal development, between the 5th and 12th weeks of gestation. During this period, neural crest cells, a remarkable population of migratory stem cells, embark on a long journey from the neural tube, down through the primitive gut, to form the enteric nervous system—the gut's intrinsic "brain." This system,

comprising the submucosal (Meissner's) and myenteric (Auerbach's) plexuses, is essential for coordinating the complex waves of muscular contraction and relaxation that constitute peristalsis. In Hirschsprung disease, this craniocaudal (head-to-tail) migration inexplicably halts prematurely. The point at which the migration stops determines the length of the affected segment. The bowel distal to this point is left devoid of ganglion cells—it is aganglionic. Without its intrinsic nervous system, this segment of bowel cannot relax.<sup>13</sup> It exists in a state of tonic spasm, creating a functional, rather than a physical, obstruction. The bowel proximal to this segment, being normally innervated, continues to contract, pushing contents against this unyielding roadblock, leading to its massive dilation. This fundamental difference in pathophysiology—an anatomical gap versus a functional blockade—dictates the entirely different surgical solutions required and underscores why the diagnostic confusion seen in this case holds such profound clinical significance. An error in diagnosis could lead to an inappropriate and disastrous surgical intervention.

The surgical management undertaken in this case was a direct and logical response to the intraoperative findings, adhering to the well-established principles for correcting ileal atresia. The first step, exploratory laparotomy, served as the final, definitive diagnostic test. Once the Type 3A atresia was identified, the goals of the surgery became clear: resect the atretic ends and restore intestinal continuity.<sup>14</sup> However, the procedure is more nuanced than simply sewing the two ends together. A critical component of the operation is the resection of a portion of the proximal, dilated bowel. While this segment is alive and well-vascularized, its structure and function have been severely compromised by chronic obstruction. It is massively dilated, hypertrophied, and its muscular walls are often edematous and ineffective. The peristaltic waves it generates are weak and uncoordinated. If this dysfunctional segment is anastomosed directly to the tiny, unused distal bowel, the result is often a functional obstruction at the

anastomosis site, leading to surgical failure. Therefore, the surgeon must resect this proximal segment back to a point where the bowel is of a more normal caliber and has better motility, typically requiring the removal of 10-15 cm. The second critical decision is the type of anastomosis. A simple end-to-end anastomosis is often not feasible due to the massive size discrepancy between the dilated proximal end and the narrow distal end. Attempting to sew these together can lead to puckering, ischemia, and a high risk of stricture. The solution, as employed in this case, is an end-to-back ileo-ascending anastomosis. The surgeon closes the blind end of the proximal bowel and then creates an anastomosis between the side of this proximal segment and the end of the distal segment. This technique creates a wide, tapering, and tension-free connection that is much more forgiving of size discrepancies and promotes better functional outcomes. The choice of suture material (absorbable monofilament like PDS) and technique (interrupted sutures) is also deliberate, designed to allow for growth and minimize inflammatory reaction in the delicate neonatal tissues. The minimal blood loss of 15 ml recorded during the operation highlights the meticulous surgical technique essential for these fragile patients.

The postoperative period proved to be as challenging as the diagnostic phase, thrusting the neonate into a physiological storm of sepsis and hypovolemic shock. This is a common and feared trajectory for neonates with delayed diagnosis of intestinal obstruction. The massively distended proximal bowel is not just a passive conduit; it is a site of significant pathology. The stasis of intestinal contents allows for massive bacterial overgrowth. The increased intraluminal pressure compromises the mucosal barrier, the delicate lining of the intestine that normally prevents bacteria from entering the bloodstream.<sup>15</sup> This breakdown allows for bacterial translocation, seeding the bloodstream, and leading to sepsis. Furthermore, the dilated bowel loops act as a "third space," sequestering large volumes of fluid, leading to profound dehydration and hypovolemia. The

onset of shock in this infant was therefore multifactorial—a combination of septic shock (from the infection) and hypovolemic shock (from fluid losses). The management of this state in a neonate is a delicate balancing act. Aggressive fluid resuscitation is necessary to restore circulating volume, but it must be done cautiously to avoid fluid overload, which a neonate's immature heart and kidneys cannot handle. The use of a low-dose dopamine infusion was a judicious choice, aimed at improving cardiac contractility and renal blood flow. The administration of broad-spectrum antibiotics (Ampicillin, Amikacin, and Metronidazole) was the cornerstone of treating the confirmed *E. coli* sepsis.<sup>16</sup> The final and equally critical pillar of postoperative support was nutrition. With the gut out of commission, total parenteral nutrition (TPN) was essential to provide the high caloric and protein demands required for healing and growth. TPN is a life-saving intervention, but it is not without its own risks. The transition to enteral feeding, initiated cautiously on the fourth postoperative day, was therefore a crucial milestone. Even tiny amounts of milk in the gut have a trophic effect, stimulating mucosal healing, promoting the release of gut hormones, and helping to prevent TPN-associated liver disease. The infant's successful navigation of this postoperative storm is a powerful testament to the capabilities of a modern, multidisciplinary neonatal intensive care unit.<sup>17</sup>

In reflecting on the entirety of this case, from the initial watery meconium to the successful follow-up visit, a clear narrative emerges. It is a narrative of diagnostic uncertainty clarified by surgical courage, of distinct pathophysiologies converging on a similar clinical picture, and of physiological crisis overcome by intensive and meticulous care.<sup>18</sup> This single patient's story serves as a microcosm of the broader challenges and triumphs in the field of pediatric surgery. It reinforces the timeless surgical principle that the clinician's hands, eyes, and judgment, informed by a deep understanding of pathophysiology, remain the most crucial diagnostic tools, especially when technology provides an ambiguous answer. It highlights that the success of a complex neonatal



operation is not measured at the moment the final suture is placed, but in the days and nights of vigilant postoperative care that follow.<sup>19</sup> The favorable outcome achieved in this case was not a matter of fortune but the direct result of a systematic, knowledgeable, and resilient approach to a life-threatening congenital anomaly.<sup>20</sup> This report, therefore, contributes to the literature not by describing a new disease or a novel surgical technique but by providing a rich, detailed, and deeply analytical account of a classic clinical challenge, offering valuable and enduring lessons for trainees and experienced practitioners alike. It champions the idea that in the world of neonatal obstruction, one must always be prepared for the unexpected and that a readiness to question, to explore, and to act is fundamental to turning a perilous situation into a story of survival and successful recovery.

#### 4. Conclusion

This case of Type 3A ileal atresia, presenting under the compelling radiological guise of Hirschsprung disease, serves as a powerful and instructive reminder of the complexities inherent in neonatal surgical care. It poignantly illustrates that while advanced imaging is an indispensable component of the diagnostic process, it is not infallible. The ultimate diagnostic responsibility rests on a thorough synthesis of the entire clinical picture, a high index of suspicion, and the courage to proceed with surgical exploration when clinical evidence and radiological findings are in conflict. The successful outcome for this neonate was forged not only in the operating room through a meticulous surgical correction but also in the intensive care unit through the aggressive and sophisticated management of severe postoperative sepsis and shock. The case definitively underscores the principle that an accurate diagnosis is the cornerstone of correct treatment and that in the fragile world of the newborn, a clear understanding of the distinct pathophysiological pathways of congenital anomalies is paramount. This report stands as a testament to the fact that even when faced with

significant diagnostic ambiguity and life-threatening complications, a steadfast application of fundamental clinical principles, combined with skilled surgical intervention and resilient critical care, can navigate the most challenging of clinical storms and guide a patient to a successful outcome.

#### 5. References

1. Santos LP, Coimbra D, Cunha C, Lopes MF. Oesophageal atresia with tracheo-oesophageal fistula, ileal atresia and Hirschsprung's disease: outcome of a rare phenotype. *BMJ Case Rep.* 2019; 12(2): e226675.
2. Ronald O, Erick O, Diana AL, Violah N, David K. Neonatal small bowel perforation in ileal atresia in a low resource setting: a case report. *Clin Case Rep.* 2020; 8(12): 3054–7.
3. Carine Sun CY, Ashok K, Mughni B. A rare case of intrauterine intussusception causing ileal atresia. *Med J Malaysia.* 2020; 75(3): 304–6.
4. Pandey A, Singh G, Shandilya G, Gupta A, Rawat J, Wakhlu A, et al. Role of Bishop–Koop Procedure for Jejunal and Proximal Ileal Atresia. *J Neonatal Surg.* 2020; 8(4): 31.
5. Dhar PP, Mohanty U. A rare case report of infant ileal atresia with double appendix. *Int J Surg Case Rep.* 2020; 74: 226–9.
6. Viggiano M, Tavares B, Neto JL. Third trimester prenatal diagnosis of meconium peritonitis following ileal atresia: Case report. *Revista Brasileira de Ultrassonografia.* 2021; 29(31): 26.
7. Yokoyama S, Nakaoka T, Nukada T, Ikeda Y, Hara S. Meconium-related ileus mimicking ileal atresia in a full-term neonate. *Pediatr Int.* 2021; 63(2): 229–31.
8. Patil N, Agnihotri R, Patil P. A case of neonatal ileal atresia with microcolon. *Res J Med Allied Health Sci.* 2021; 3(2): 19–22.
9. Mrindoko P, Mselle M, Meleki E, Kimambo E, Mchaile D, Lodhia J. Ileal Atresia in a 10-day-

- old male baby: a case report. *SAGE Open Med Case Rep.* 2021; 9: 2050313X211042983.
10. Daib A, Lindolsi M, Hellal Y, Boughdir M, Ben Abdallah R, Kaabar N. A rare association of ileal atresia and total colonic Hirschsprung's disease. *J Pediatr Surg Case Rep.* 2022; 77(102111): 102111.
  11. Agrawal A. An unusual case of ileal atresia: a case report. *Arch Clin Trial & Case Rep.* 2022.
  12. Toyama C, Segawa Y, Iijima S, Murakoshi T, Nara K. Intestinal volvulus in utero causing torsion of dilated bowel with ileal atresia: a case report. *Surg Case Rep.* 2023; 9(1):65.
  13. Mili T, Charieg A, Ezzine R, Ben Ahmed Y, Jlidi S. Congenital mesenteric defect with distal ileal atresia and segmental volvulus in a neonate: a case report. *J Pediatr Surg Case Rep.* 2023; 95(102664): 102664.
  14. Ai J, Xia C, Yang D. Ileal substitution for bilateral ureters in the treatment of a case of unexplained bilateral long-segment ureteral atresia. *Asian J Surg.* 2024; 47(11): 4839–40.
  15. Ahmed Qureshi M, Muhammed Aslam S, Ahmed Qureshi I. Umbilical polyp, Meckel's diverticulum, and incomplete type-1 ileal atresia: a case report. *J Pediatr Surg Case Rep.* 2024; 102(102784): 102784.
  16. Rekavari SG, Khedkar K, Mahakalkar C, Gianchandani S. Surgical management of omphalocele with concurrent ileal atresia: a case report. *Cureus.* 2024; 16(4): e59147.
  17. Hencke J, Diez O, Loff S. A remarkable case of intrauterine intussusception, ileal atresia, and complicated meconium ileus: a case report. *J Neonatal Surg.* 2024; 13: 21.
  18. Prashanth RR, Jyothi S, Haribalakrishna A. A rare case of polysplenia syndrome associated with atrioventricular canal defect and type four ileal atresia in a preterm neonate: a case report and literature review. *Wadia J Women Child Health.* 2024; 3(35): 35–9.
  19. Prasad P, Radha P, Kumar B, Kanneganti P. Extensive intramural calcification in neonatal ileal atresia: an unusual finding. *Indian J Pathol Microbiol.* 2024; 67(3): 703–5.
  20. Sudai FM, Yakayashi M, Mwangobele L, Kafubhi P, Ntabudyo H, Magembe KJ, et al. Challenges in managing neonatal ileal atresia in limited-resource settings: a case report. *Pan Afr Med J.* 2024; 48: 125.